



## PATIENT

Dominic Franklin

## SPECIES

Feline

## BREED

DSH

## SEX

MN

## AGE

12 y

## WEIGHT

13 lb

## PRESENTING CLINICAL SIGNS

New grade 2/6 murmur. BNP 124. CBC/Chem/T4 WNL.

## ECHOCARDIOGRAPHIC FINDINGS

2D, M-mode, and Doppler study.

Left atrial size is normal. The mitral valve is normal. Left ventricular wall thickness is normal. Left ventricular internal dimensions are normal. Left ventricular systolic function is hyperdynamic. The aorta and aortic valve are normal. Right atrial and right ventricular dimensions are normal. The tricuspid valve is normal. The pulmonary artery and pulmonic valve are normal. No shunting lesions are visualized. No pericardial effusion or cardiac masses are seen.

LA/Ao - 1.32

IVSd - 4.9 mm

LVPWd - 4.9 mm

LVIDd - 15.4 mm

LVIDs - 5.9 mm

FS - 61.7%

LVOT - 1.07 m/s

RVOT - 1.06 m/s

## ASSESSMENT/RECOMMENDATIONS

Normal echocardiogram

This examination demonstrates no evidence of structural heart disease. As such, no reason for Dominic's murmur or BNP elevation is appreciated in the image set. It's likely that Dominic's murmur is functional/innocent and his BNP is a false positive, though systemic hypertension should be ruled out as a possible cause of both.

No therapy is recommended based on this exam.

A recheck echocardiogram is recommended if the characteristics of Dominic's murmur change, or if other new physical exam and/or clinical signs compatible with cardiac dysfunction develop.

## INTERPRETED BY

Keith Blass, DVM, MS,  
DACVIM (Cardiology)

## IMAGING PERFORMED BY

Karen Ebersole, DVM,  
DABVP

## HOSPITAL NAME

Scanvet

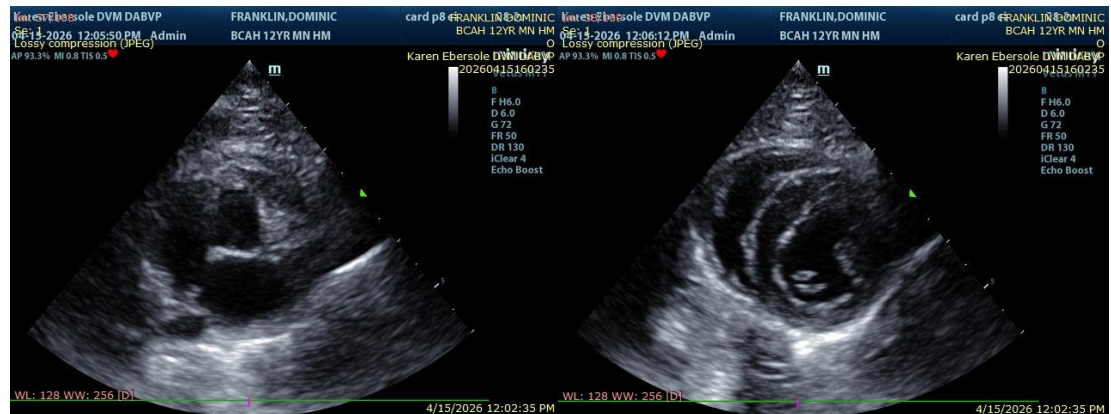
## REFERRING VET

Dr. Golden

## INVOICE

## DATE

4/15/26



The information and recommendations provided are based on the images presented by the referring



## PATIENT

Dominic Franklin

## SPECIES

Feline

## BREED

DSH

## SEX

MN

## AGE

12 y

## WEIGHT

13 lb

## INTERPRETED BY

Keith Blass, DVM, MS,  
DACVIM (Cardiology)

## IMAGING PERFORMED BY

Karen Ebersole, DVM,  
DABVP

## HOSPITAL NAME

Scanvet

## REFERRING VET

Dr. Golden

## INVOICE

## DATE

4/15/26

veterinarian/sonographer. No evaluation can be communicated regarding pathology that was not visible in the image/video clips provided.

Thank you for this referral. If the clinical or image interpretation does not parallel your findings or if I can be of any further assistance please contact me.

**Keith Blass, DVM, MS, DACVIM (Cardiology)**

[info@SonoPath.com](mailto:info@SonoPath.com)